

A Case of Unilateral Duplication of the Axillary Vein: A Rare Anatomical Variant

KANCHARLA EMMANUEL¹, SURRAJ SUSAI², MRUDULA CHANDRUPATLA³, BHUSHAN BAGUL⁴, NIKITA ALWAL⁵

(CC) BY-NC-ND

ABSTRACT

The axillary vein, being the principal vein of the axilla, is usually formed as a continuation of the basilic vein and drains the majority of the upper limb. Its duplication, as observed in this cadaver, is quite rare. Although many reports have emphasised the variations in the axillary artery, there are very few that have focused on the variant anatomy of the axillary veins. In this case report, a variant anomaly of the axillary veins was found while routinely dissecting the axilla in a formalin-fixed male cadaver. In this cadaver, the left axilla had two axillary veins. The thoracodorsal vein drained into the medial axillary vein, while the cephalic vein appeared to drain into the lateral axillary vein. Surgical implications regarding catheterisations are likely to arise as a result of these venous variants. A thorough understanding of the variant anatomy of these veins is essential for surgeons during operations in the axilla. A duplicated axillary vein may impede the route of catheters inserted into the heart and might also obstruct the laminar flow of blood into the subclavian vein. This case report serves as an indicator to encourage further typing and patterned studies on the numerical abnormalities pertaining to the angulations and number of axillary veins, in order to provide guidance for cardiovascular surgeons during their venous access procedures.

Keywords: Anomalies, Cadaveric study, Double veins, Upper limbs

CASE REPORT

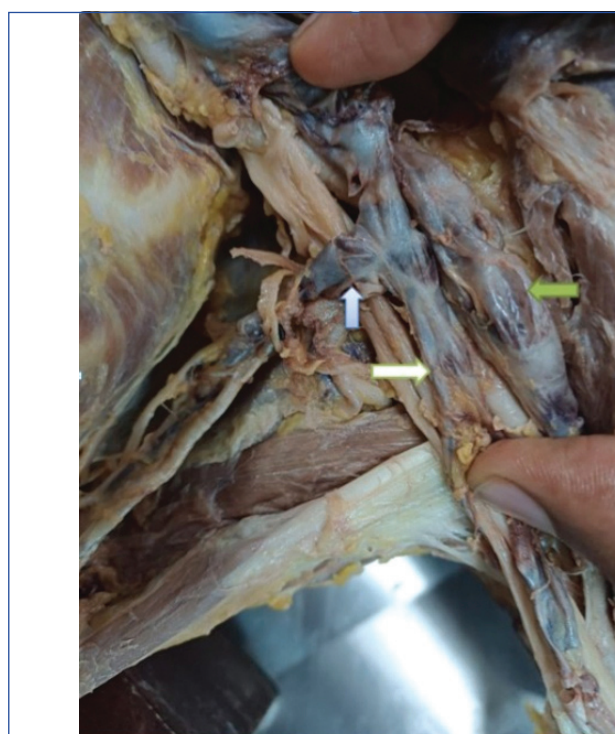
This case report was conducted following ethics exemption approval. The ethics committee exemption approval number is AIIMS/BBN/IEC/Nov 2024/598-Exem. The finding was observed in a 69-year-old male cadaver that was procured for the anatomy department's cadaveric laboratory within 48 hours of death. The cause of death for this cadaver was myocardial infarction. It was a lean cadaver with no signs of decomposition. During routine teaching and demonstration sessions for undergraduate medical students, this finding was reported. The procedural steps outlined in Cunningham's dissection manual were used to dissect the axilla in a sequential manner and the axillary veins on both sides were observed [1].

Incisions were made from the anterior axillary fold, lines up to the middle of the arm and then horizontally across the arm to remove the skin as two flaps in and around the axilla [1]. The midpoint of the clavicle and the midpoint of the humerus were used as bony anatomical landmarks for tracing the axillary veins, as the veins were confined within these landmarks [1]. The axillary pad of fat was removed along with the axillary groups of lymph nodes to obtain a clear view of the axillary veins on both sides.

On the left side, it was observed that there were two axillary veins [Table/Fig-1,2]. Of the two veins, the thoracodorsal vein was found to drain into the medial axillary vein [Table/Fig-1]. Toward the inner border of the left first rib, the lateral axillary vein united with its medial counterpart to form a common entity before continuing as the subclavian vein [Table/Fig-2]. The cephalic vein was found to drain into the common fused vein rather than into the axillary or subclavian vein [Table/Fig-1,2]. On the right side, however, only a single axillary vein was observed [Table/Fig-3].

DISCUSSION

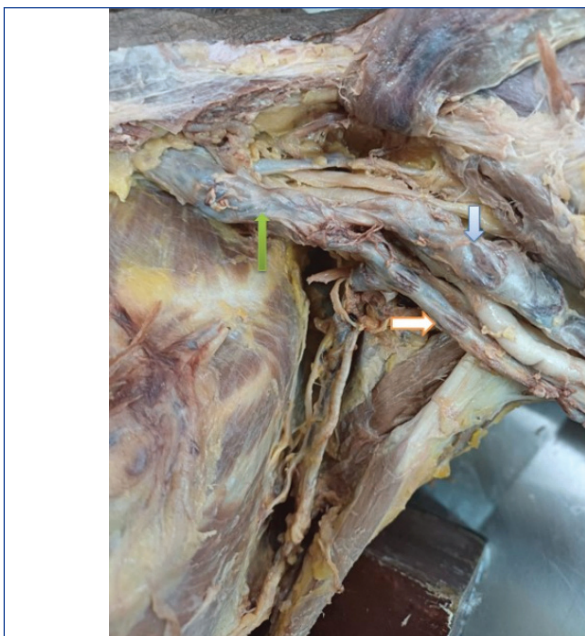The axillary vein, being the principal vein of the axilla, lies close to its medial wall. It is the medialmost structure among the vessels in the axilla. It is located medial to the axillary artery and drains into the subclavian vein beyond the outer border of the first rib [1,2]. This vein is especially important when performing venous catheterisations into the veins of the heart, as it serves as a guide for directing the



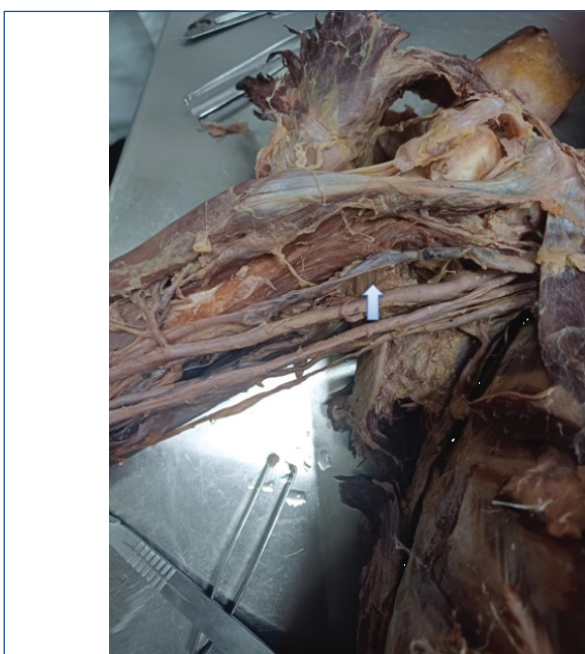[Table/Fig-1]: Left thoracodorsal vein (blue arrow) drains into left medial axillary vein (white arrow) and lateral axillary vein is independent (green arrow).

catheter into the appropriate heart chamber from the cephalic vein, which drains into it at an acute angle [2,3]. Anomalies regarding the axillary vein, particularly duplication anomalies, are quite rare and are seldom reported. In this cadaver, a double axillary vein was found in the left axilla. This may have implications for surgical approaches to the same [3,4].

Sollazzo V et al., reported multiple venous anomalies in the upper limb, including the duplications of the axillary vein along with triplications of the cephalic and basilic veins. However, in this cadaver, a unilateral duplication of the axillary veins alone was observed, which appeared to be mirror images of each other [2]. According to Sollazzo V et al., axillary vein duplications are likely



[Table/Fig-2]: Left medial axillary vein (white arrow) and left lateral axillary vein (blue arrow) unite proximally to form a common fused vein (green arrow).



[Table/Fig-3]: Right single normal axillary vein.

to occur if there are underlying mesenchymal connective tissue abnormalities [2]; however, no such connective tissue anomalies were found in this cadaver.

According to Yang HJ et al., the cephalic vein drained directly into the subclavian vein whenever the axillary veins were duplicated. However, the findings in this cadaver were slightly contrary to Yang HJ et al., because the cephalic vein in this cadaver drained into one of the axillary veins on the lateral side [3]. Lee H et al., observed that the tributaries of the axillary vein were not always mirror images of the branches of the axillary artery. The findings in this report agree with those of Lee H et al., as in this cadaver, the thoracodorsal vein was found to drain into the medial axillary vein and no other tributaries were observed [4]. Additionally, the cephalic vein drained into the lateral axillary vein, and the basilic vein was absent.

Roy TS et al., observed that the medial cutaneous nerve of the forearm pierced the axillary vein, and they found a so-called fenestrated axillary vein on both sides [5]. However, this cadaver revealed no such findings, and no nerve was found to pierce the duplicated axillary veins. Jalota Sahota R et al., postulated that duplications or triplications in the axillary vein are more prone to

produce thrombi in the subclavian veins due to pressure differences between them [6]. This was more evident in this cadaver because both veins drained at acute angles to each other, including at the junction of the cephalic and axillary veins. This could have serious implications for ultrasound-guided catheterisations in patients, as well as for performing venipunctures [7,8].

Hadimani S et al., found a variant branch of the axillary artery that fenestrated the axillary vein [9]; however, in this cadaver, the axillary artery was found to be bridged between the two axillary veins. These variant anomalies of the axillary veins are most likely produced due to the faulty union of primitive basilic veins with the preaxial veins of the upper limbs [10]. During the fourth to sixth weeks of foetal life, the preaxial and postaxial arteries of the primitive upper limb buds develop their own separate venae comitantes due to mesenchymal neogenesis [11]. However, since this mesenchymal proliferation exceeds that of vascularisation, the primitive upper limb veins may sometimes undergo excessive zygois at improper angles, leading to duplications of axillary veins [10,11].

This may or may not be accompanied by mesenchymal anomalies, as observed in this cadaver, where duplication of the axillary veins occurred without any marked connective tissue or mesenchymal anomalies, contrary to the findings of Sollazzo V et al., [2]. Thrombi formation is prone to occur in such duplicated veins due to the reduction in laminar flow of blood [12,13]. Venous catheterisations also become increasingly difficult in such cases due to the abnormal sharpness of the angulations between the veins [13,14].

CONCLUSION(S)

Duplications of the axillary veins are unusually rare. They can lead to thrombi in the surrounding veins and may also cause difficulties in venipuncture and catheterisations. A thorough knowledge of the existing patterns of the axillary veins is essential for preventing the aforementioned problems during cardiac venous access surgeries. Additionally, understanding their deviant morphological courses can enhance our comprehension of the embryology of axillary veins.

REFERENCES

- [1] Romanes GJ, Koshi R. Cunningham's Manual of Practical Anatomy. Vol 2. 16th edn. Oxford: Oxford University Press; 2017. pp. 126-30.
- [2] Sollazzo V, Luglio G, Esposito E, Di Micco R, Giglio MC, Peltrini R, et al. Venous anomalies of the axilla: A single-institution experience. *Aging Clin Exp Res*. 2017;29(Suppl 1):139-42. Doi: 10.1007/s40520-016-0673-8. Epub 2016 Nov 22. PMID: 27878556.
- [3] Yang HJ, Gil YC, Jin JD, Cho H, Kim H, Lee HY. Novel findings of the anatomy and variations of the axillary vein and its tributaries. *Clin Anat*. 2012;25(7):893-902. Doi: 10.1002/ca.22086. Epub 2012 May 23. PMID: 22623347.
- [4] Lee H, Bang J, Kim S, Yang H. The axillary vein and its tributaries are not in the mirror image of the axillary artery and its branches. *PLoS One*. 2019;14(1):e0210464. Doi: 10.1371/journal.pone.0210464. Erratum in: *PLoS One*. 2020;15(3):e0230471. Doi: 10.1371/journal.pone.0230471. PMID: 30629680; PMCID: PMC6328140.
- [5] Roy TS, Sharma S. Axillary vein perforation by the medial cutaneous nerve of the forearm. *Clin Anat*. 2004;17(4):300-02. Doi: 10.1002/ca.10237. PMID: 15108333.
- [6] Jalota Sahota R, Lottfollahzadeh S, Soos MP. Subclavian vein thrombosis. [Updated 2023 Jun 3]. In: StatPearls [Internet]. Treasure Island (FL): StatPearls Publishing; 2024 Jan. Available from: <https://www.ncbi.nlm.nih.gov/books/NBK559269/>.
- [7] Azoulay D, Salloum C, Lahat E, Eshkenazi R, Lim C. A new extra-thoracic, in-plane, longitudinal, real-time, ultrasound-guided access to the axillary vein. *Intensive Care Med*. 2019;45(6):876-80. Doi: 10.1007/s00134-019-05561-w. Epub 2019 Feb 13. PMID: 30758521.
- [8] Yao M, Xiong W, Xu L, Ge F. A modified approach for ultrasound-guided axillary venipuncture in the infraclavicular area: A retrospective observational study. *J Vasc Access*. 2019;20(6):630-35. Doi: 10.1177/1129729819838135. Epub 2019 Mar 28. PMID: 30919718.
- [9] Hadimani S, Desai SD, Bagoji IB, Patil BS. Fenestration of axillary vein by a variant axillary artery. *Kathmandu Univ Med J (KUMJ)*. 2013;11(42):162-64. Doi: 10.3126/kumj.v11i2.12494. PMID: 24096226.
- [10] Araújo RC, Pires LAS, Andrade ML, Perez MC, Filho CSL, Babinski MA. Embryological and comparative description of the cephalic vein joining the external jugular vein: A case report. *Morphologie*. 2018;102(336):44-47. Doi: 10.1016/j.morpho.2017.10.002. Epub 2017 Nov 11. PMID: 29133232.

[11]

Nguyen JD, Duong H. Anatomy, shoulder and upper limb, veins. [Updated 2023 Aug 14]. In: StatPearls [Internet]. Treasure Island (FL): StatPearls Publishing; 2025 Jan. Available from: <https://www.ncbi.nlm.nih.gov/books/NBK546676/>.

[12]

Altıparmak B, Korkmaz Tokar M, Uysal AI, Gümüş Demirebilek S. Double axillary vein variation diagnosed with ultrasound guidance during infraclavicular nerve block intervention. *BMJ Case Rep.* 2019;12(1):bcr-2018-227495. Doi: 10.1136/bcr-2018-227495. PMID: 30696646; PMCID: PMC6350747.

[13]

Fujii T, Yajima R, Yamaguchi S, Kuwano H. Double axillary vein: A case detected by CT. *Int J Case Reports and Images.* 2012;3(10):58-59.

[14]

Kaczorowski J, Lasocka-Koriat Z, Spodnik JH, Majak K, Sidor-Kaczmarek J, Kowiariski P. Rare variations of cephalic vein drainage: Two case reports. *Folia Morphol (Warsz).* 2024;83(3):740-44. Doi: 10.5603/fm.96440. PMID: 37889220. Epub 2023 Oct 27.

PARTICULARS OF CONTRIBUTORS:

1. Senior Resident, Department of Anatomy, AIIMS Bibinagar, Hyderabad, Telangana, India.
2. Associate Professor, Department of Anatomy, AIIMS Bibinagar, Hyderabad, Telangana, India.
3. Professor and Head, Department of Anatomy, AIIMS Bibinagar, Hyderabad, Telangana, India.
4. Undergraduate Student, Department of Anatomy, AIIMS Bibinagar, Hyderabad, Telangana, India.
5. Undergraduate Student, Department of Anatomy, AIIMS Bibinagar, Hyderabad, Telangana, India.

NAME, ADDRESS, E-MAIL ID OF THE CORRESPONDING AUTHOR:

Dr. Surraj Susai,
Ground Floor, Department of Anatomy, AIIMS Bibinagar, Yadadri,
Hyderabad-508126, Telangana, India.
E-mail: surraj18@gmail.com

PLAGIARISM CHECKING METHODS: [\[Lain H et al.\]](#)

- Plagiarism X-checker: Jan 30, 2025
- Manual Googling: Feb 20, 2025
- iThenticate Software: Mar 05, 2025 (14%)

ETYMOLOGY: Author Origin

EMENDATIONS: 6

AUTHOR DECLARATION:

- Financial or Other Competing Interests: None
- Was informed consent obtained from the subjects involved in the study? Yes
- For any images presented appropriate consent has been obtained from the subjects. Yes

Date of Submission: **Jan 29, 2025**
Date of Peer Review: **Feb 17, 2025**
Date of Acceptance: **Mar 07, 2025**
Date of Publishing: **Apr 01, 2025**